ARTICLE IN PRESS

Current Problems in Diagnostic Radiology xxx (xxxx) xxx

Contents lists available at ScienceDirect

Current Problems in Diagnostic Radiology

journal homepage: www.cpdrjournal.com

Original Article

Advancing preoperative staging in early breast cancer: A comparative analysis of imaging modalities

André Mattar, MD, PhD [a,b,*], Almir Bitencourt, MD, PhD [c], Flora Finguerman Menache Dwek, MD, PhD [c], Andressa Amorim, MD [a], Luiz Henrique Gebrim, MD, PhD [d], Marcelo Antonini, MD, PhD [b,e], Henrique Lima Couto, MD, PhD [f], Flavia Paiva, MD, PhD [c]

[a] Hospital da Mulher, São Paulo, SP, Brazil
[b] BBREAST: Brazilian Breast Cancer Associate Research Team, Brazil
[c] Dasa /Alta Excelência Diagnóstica, Radiodiagnóstico por Imagem, SP, Brazil
[d] Hospital Beneficência Portuguesa, São Paulo, SP, Brazil
[e] Hospital do Servidor Público Estadual, São Paulo, SP, Brazil
[f] Redimama - Redimasto, Belo Horizonte, MG, Brazil

ARTICLE INFO

Keywords:
Contrast-enhanced mammography
Magnetic resonance imaging
Tumor size
Breast cancer
Early diagnosis

ABSTRACT

Background and Purpose: Accurate preoperative staging is essential for guiding surgical planning and optimizing outcomes in early-stage breast cancer. Magnetic resonance imaging (MRI) is considered the gold standard but is often limited by cost and availability. This study aimed to prospectively compare the diagnostic performance of full-field digital mammography (FFDM), digital breast tomosynthesis (DBT), contrast-enhanced mammography (CEM), and MRI for tumor detection and size estimation in patients eligible for upfront surgery.

Materials and Methods: This single-center, prospective study included 46 women with histologically confirmed early-stage invasive breast cancer. All patients underwent FFDM, DBT, CEM, and MRI within one week prior to surgery. Histopathology served as the reference standard. Tumor size measurements were compared using Pearson's correlation coefficients (r), with concordance defined as a size difference within ±10 mm. Detection rates, size accuracy, and ability to identify multifocal lesions were evaluated.

Results: The mean patient age was 55.4 years. FFDM identified the primary tumor in 89.1% of cases, DBT in 97.8%, and both CEM and MRI in 100%. Tumor size correlation with pathology was highest for MRI (r=0.811), followed by CEM (r=0.660), DBT (r=0.636), and FFDM (r=0.314). Concordance with pathology was 80.4% for MRI, 71.7% for CEM and DBT, and 58.7% for FFDM. Multifocal disease was detected in 15.2% of cases by MRI, 8.7% by DBT, and 6.5% by CEM.

Conclusion: CEM and DBT showed strong diagnostic performance and may serve as accessible and cost-effective alternatives to MRI for preoperative staging in early-stage breast cancer. These modalities offer valuable imaging options in settings where MRI is limited or contraindicated.

Introduction

Breast cancer (BC) is a prevalent malignancy worldwide, with 2,3 million new cases globally and responsible for 660,00 deaths annually[1]. In Brazil alone, 73,250 new cases were estimated in 2023, with a substantial proportion diagnosed at advanced stages[2]. Early detection and accurate preoperative locoregional staging are essential for optimal surgical planning, guiding adjuvant therapy decisions, and improving overall outcomes.

Preoperative locoregional staging plays a pivotal role in surgical planning for breast cancer patients. It determines tumor extent, identifies multifocal or multicentric disease, and detects contralateral lesions, all of which influence the choice between breast-conserving surgery and mastectomy, as well as the need for axillary management. Accurate tumor size estimation is particularly crucial, as it directly impacts clinical staging, prognosis, and adjuvant treatment decisions.

* Corresponding author at: Hospital da Mulher-SP, Av. Rio Branco, 1080 - Campos Elíseos- São Paulo - SP, 01206-001, Brazil.
E-mail address: mattar.andre@gmail.com (A. Mattar).

https://doi.org/10.1067/j.cpradiol.2025.08.014

Available online 23 August 2025
0363-0188/© 2025 Elsevier Inc. All rights are reserved, including those for text and data mining, AI training, and similar technologies.

Please cite this article as: André Mattar et al., *Current Problems in Diagnostic Radiology,* https://doi.org/10.1067/j.cpradiol.2025.08.014

Currently, upfront surgery is typically indicated in early-stage breast cancer when there is a favorable tumor-to-breast ratio and no clear need for neoadjuvant systemic therapy[3], such as in luminal tumors. While neoadjuvant treatment is often preferred in aggressive subtypes like HER2-positive and triple-negative breast cancer, patients with luminal tumors may proceed directly to surgery depending on tumor characteristics[4,5].

Among imaging modalities, magnetic resonance imaging (MRI) is widely regarded as the most sensitive technique for locoregional staging[6] and offers superior soft tissue contrast and dynamic contrast enhancement, facilitating the detection of multifocal, multicentric, and contralateral disease[6–8]. However, MRI has several limitations, including high cost, longer acquisition times, limited availability, and contraindications in patients with claustrophobia or implanted metallic devices[9]. Moreover, studies have raised concerns about MRI's potential to increase mastectomy rates without improving surgical outcomes[10]. It is noteworthy that MRI is costly, time-consuming, and may be limited by patient claustrophobia, precluding its use in some cases.

Digital breast tomosynthesis (DBT), another advanced imaging technique, improves upon conventional full-field digital mammography (FFDM) by reducing tissue overlap and enhancing lesion conspicuity. DBT has shown better performance than FFDM in detecting breast cancers and in more accurately estimating tumor size[11]. However, its ability to detect multifocal or multicentric disease remains inferior to that of functional imaging modalities like contrast-enhanced mammography (CEM) and MRI[12].

CEM has emerged as a promising alternative to MRI[13,14]. CEM combines anatomical and functional imaging by using iodinated contrast media to highlight areas of increased vascularity, similar to MRI. Several studies have demonstrated that CEM offers comparable sensitivity to MRI for lesion detection while being more accessible, faster, and better tolerated by patients[15–17]. The addition of contrast-enhanced imaging can improve lesion extent accuracy, facilitating more appropriate surgery, particularly in women with dense breasts.

CEM uniquely combines anatomical and functional data, revealing underlying masses and architectural distortions challenging to interpret with DM due to glandular breast tissue overlap[18]. Given its novelty, there are no established guidelines for routine CEM use in preoperative assessment of newly diagnosed breast cancer patients. Current indications align with those accepted for MRI, as both techniques are based on vascular enhancement principles, providing functional information[19–21].

Despite the growing body of evidence supporting the use of CEM and DBT, there is limited prospective data directly comparing FFDM, DBT, CEM, and MRI for preoperative staging in the same patient cohort. In addition, few studies have focused exclusively on early-stage breast cancer patients eligible for upfront surgery, a clinically distinct subgroup in whom accurate tumor sizing and lesion detection are critical.

Therefore, the purpose of this prospective study was to compare the performance of FFDM, DBT, CEM, and MRI in the preoperative locoregional staging of patients with early-stage breast cancer, using histopathology as the gold standard. We aimed to assess the correlation of tumor size between imaging modalities and pathology, the detection rates of additional lesions, and the potential role of CEM and DBT as accessible alternatives to MRI in this specific clinical scenario.

Methods

This was a prospective, single-center diagnostic accuracy study designed to compare the performance of full-field digital mammography (FFDM), digital breast tomosynthesis (DBT), contrast-enhanced mammography (CEM), and magnetic resonance imaging (MRI) in the preoperative locoregional staging of early-stage breast cancer. All imaging examinations were conducted within one week prior to surgery. The study was conducted at Pérola Byington Hospital - Women's Health Reference Center (CRSM-SP), with imaging performed at Alta Excelência Diagnóstica (DASA).

Sample size

This pilot study used a convenience sample of patients enrolled between March 2021 and June 2022. A post hoc power analysis was performed based on the primary endpoint (correlation of tumor size between imaging modalities and pathology). Considering an expected correlation coefficient (r) of 0.7 between modalities, an alpha error of 5%, and a power of 80%, the required sample size would be approximately 20 patients. Therefore, we decided to include 56 patients to exceed the required number for detecting meaningful differences in tumor size correlation.

Inclusion criteria

Eligible participants were female patients diagnosed with breast cancer according to the World Health Organization (WHO) criteria, followed up in the Mastology outpatient clinic at Pérola Byington Hospital. All participants provided informed consent by signing the Free and Informed Consent Form.

We included participants aged > 18 years, female gender, clinical stage I or II at diagnosis, staging exams showing no evidence of systemic disease, no prior treatment and eligible for upfront surgical treatment.

Exclusion criteria

We excluded those with contraindications for breast MRI (e.g., metal implants), claustrophobia and patients with decompensated clinical comorbidities preventing prone position during the exam. This criterion was applied to exclude patients unable to tolerate the examination due to discomfort or significant comorbidities. We also excluded patients with a history of allergic reaction to paramagnetic or iodinated contrast agents, chronic renal insufficiency on dialysis, personal history of breast cancer treated surgically within the last 12 months, pregnancy or lactation within the last 6 months, contraindication for surgery, those who did not perform all stablished exams in the protocol, patients undergoing neoadjuvant chemotherapy and those with tumors completely resected during initial biopsy.

Data collection

All clinical data was collected in the patient's medical record, completed by the executing researcher. These records were archived and transferred to an online computerized system.

At least one researcher was present at the outpatient clinic for newly diagnosed breast cancer patients at Pérola Byington Hospital during the initial consultation. Eligible patients were identified by one of the researchers (AM or AA), who completed the medical record and collect data. Candidates for the study were evaluated through physical examination and clinical tumor measurement was made using calipers and then were referred to perform within one week prior to surgery, to FFDM, DBT, CEM and MRI. After the exams patients were submitted to surgery by the Mastology team at Pérola Byington Hospital and were followed up according to the institution's protocol.

Image acquisition

FFDM: Performed using a Hologic Selenia system (Hologic, USA). Standard craniocaudal (CC) and mediolateral oblique (MLO, 30-60°) views were acquired with automatic exposure control. Images were analyzed on high-resolution diagnostic monitors by breast imaging specialists.

DBT: Acquired immediately following FFDM in the same session using the same Hologic Selenia unit. DBT was performed in standard CC

and MLO projections, using a step-and-shoot method with a 15° angular range and a total of 15 projections per view.

CEM: After DBT, all CEM studies were performed on a MAMMOMAT Revelation system (Siemens Healthineers, Germany) equipped for dual-energy contrast-enhanced acquisition. A nonionic iodinated contrast agent, Optiray® 320 (ioversol 68%) was administered intravenously at a dose of 1.5 mL/kg body weight using an automated power injector at a rate of 3 mL/s, followed by a 30 mL saline flush to ensure complete bolus delivery.

Imaging began 2 minutes after injection, corresponding to the peak parenchymal and lesion enhancement phase. For each breast, bilateral CC and MLO views were acquired under standard compression, with the patient in a standing position. In each projection, the system automatically obtained:

Low-energy exposure (26–30 kVp) to depict anatomical detail without significant iodine attenuation.

High-energy exposure (45–49 kVp) optimized to capture iodine's K-edge signal.

The MAMMOMAT Revelation system's proprietary recombination algorithm automatically processed the paired low- and high-energy images to produce recombined contrast images, suppressing background parenchymal signal and highlighting foci of iodine uptake.

No delayed projections were performed, ensuring consistent timing across all patients. Total examination time, from contrast injection to completion of the last projection, was approximately 7–10 minutes.

MRI: Performed after 3 days after CEM. All MRI examinations were performed on a 1.5 Tesla Signa HDxt scanner (GE Healthcare, USA) using a dedicated 8-channel bilateral breast coil with the patient in the prone position. The protocol followed the recommendations of the American College of Radiology Breast MRI Practice Parameter and included the following sequences:

Localizer sequences in three orthogonal planes for positioning.

Axial T1-weighted images without fat suppression for anatomical reference.

Axial fat-suppressed T2-weighted images for lesion characterization and detection of associated edema or cystic components.

Dynamic contrast-enhanced (DCE) imaging:

Axial 3D fast spoiled gradient echo (FSPGR) sequence with fat suppression.

Acquisition performed before contrast injection (pre-contrast) and repeated at multiple post-contrast time points (four dynamic phases in total).

Temporal resolution approximately 60–90 seconds per phase.

A gadolinium-based contrast agent (gadopentetate dimeglumine, 0.1 mmol/kg body weight) was injected intravenously via an automated power injector at a rate of 2 mL/s, followed by a 20 mL saline flush. The first post-contrast phase began within 20–30 seconds of injection to capture the early enhancement phase.

Images were post-processed to generate subtraction images and maximum intensity projections (MIPs) for each post-contrast phase. Lesions were evaluated for morphology and enhancement kinetics using the ACR BI-RADS® MRI lexicon, including time–intensity curve assessment. Total examination time was approximately 15-20 minutes.

Image analysis

All images were analyzed on a dedicated computer by the mammography radiology team at Alta Excelência Diagnóstica (Dasa) with >10 years of experience. Images were analyzed using dedicated computers for each modality, following the ACR BI-RADS® Atlas guidelines. Conventional and contrast mammography reported parenchymal density, lesion dimensions, shape, and margins. MRI reported post-contrast parenchymal enhancement, lesion dimensions, shape, margins, and dynamic enhancement curves, with all reports including an ACR BI-RADS® category and corresponding recommendation. All examinations (FFDM, DBT, CEM, and MRI) were interpreted specifically for the purpose of this study by the same breast radiologist, who had over 10 years of experience in breast imaging. Dedicated reading sessions were conducted for each modality, with a minimum washout period of 2 weeks between the interpretation of different modalities for the same patient to minimize recall bias.

Histopatological analysis

Surgical specimens were analyzed following the College of American Pathologists (CAP) guidelines, considering tumor measurement, the size of the largest lymph node metastasis, and the number of positive lymph nodes.

Ethical aspects

The present study was approved by the local Research Ethics Committee under the number CAAE: 44972721.1.0000.0069 and was conducted in compliance with the Helsinki Declaration.

Results

Between March 2021 and December 2022, we included 56 enrolled patients, 10 were excluded (eight did not perform either CEM or MRI; one performed neoadjuvant treatment; and one did not have residual tumor at surgery). Thus, 46 patients were analyzed in the study (Fig. 1), with mean age of 55.4 years (range: 43-73 years). In Table 1 we summarize baseline characteristics of the studied population.

Most patients had no special type (NST) invasive breast carcinoma (n=43; 93.4%) and the most common molecular subtype was Luminal A (n=25; 54.3%). At clinical assessment, most of patients (n=27 – 58.7%) were classified as T2. After surgical resection, mean tumor size was 2.8 ± 1.4 cm (range: 1.0-8.0 cm), and pathological staging showed 16 (34.7%) T1, 28 (60.9%) T2 e 2 (4.4%) T3.

The main tumor was identified in 41 cases (89.1%) by FFDM, 45 (97.8%) by DBT, and in all cases (100%) by both CEM and MRI. One example of this correlatios between the methods is show in Fig. 2. Mean tumor size was 1.8 ± 0.9 cm for FFDM, 2.3 ± 1.0 cm for DBT, 2.3 ± 0.9 cm for CEM, and 2.5 ± 1.2 cm for MRI. A strong correlation in tumor size was observed between CEM and MRI ($r=0.902$; $p<0.01$), and between CEM and DBT ($r=0.952$; $p<0.01$).

DBT, CEM and MRI demonstrated significant correlation with the tumor size at pathology ($p<0.01$), whereas FFDM did not ($p=0.34$). Tumor size agreement with pathology was 58.7% for FFDM, 71.7% for DBT and CEM, and 80.4% for MRI (Table 2). MRI also showed better reliability and agreement with pathologic tumor stage (Table 3).

Table 4 summarizes the performance of each imaging modality regarding main tumor detection rate, mean tumor size estimation, and multifocal lesion detection. Both CEM and MRI achieved a 100% detection rate for the primary tumor, with MRI demonstrating the highest mean tumor size measurement (2.5 ± 1.2 cm) and the greatest rate of multifocal lesion detection (15.2%). DBT also showed a high detection rate (97.8%) and identified multifocal lesions in 8.7% of cases, while FFDM had the lowest detection rate (89.1%) and failed to detect multifocal lesions. In one case, a 0.7 cm invasive carcinoma in the contralateral breast was confirmed by both MRI and CEM modalities. Although MRI identified a numerically higher rate of multifocal lesions than CEM, formal statistical testing was underpowered due to the small number of cases. Thus, while MRI numerically outperformed CEM, there was no statistically significant superiority. MRI ($r=0.811$) vs. CEM ($r=0.660$) showed no statistically significant difference ($p=0.18$). One example of contralateral disease is shown in Fig. 3.

Discussion

In this prospective head-to-head comparison, we evaluated the diagnostic performance of FFDM, DBT, CEM, and MRI in the

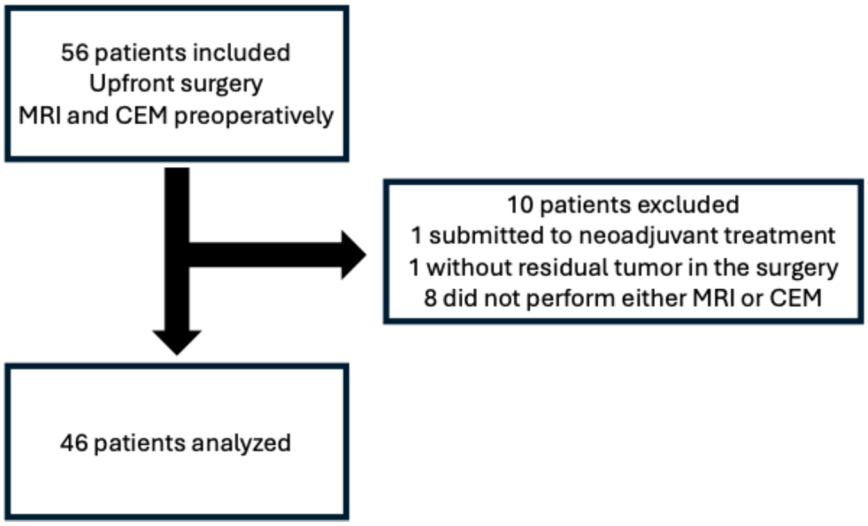

Fig. 1. Trial design.

Table 1
– Baseline Characteristics of the population.

Characteristic	Patients (n=46)
Mean Age (range) in years	55.4 (43-73)
Sex, n (%) female	46 (100.0)
Pathological type (n, %)	
No special type (NST) invasive breast carcinoma	43 (93.4)
Mixed lobular and NST invasive carcinomas	1 (2.2)
Mucinous carcinoma	1 (2.2)
Invasive lobular carcinoma	1 (2.2)
Molecular subtype (n, %)	
Luminal A	25 (54.3)
Luminal B	16 (34.8)
Triple-negative	3 (6.5)
Luminal with HER2 overexpressed	2 (4.4)
Clinical assessment (n, %)	
T1	19 (41.3)
T2	27 (58.7)
Post surgical pathological staging (n, %)	
T1	16 (34.7)
T2	28 (60.9)
T3	2 (4.4)

preoperative staging of early-stage breast cancer.

Tumor size estimation and staging concordance

Tumor size estimation is critical for surgical planning and prognostication. Breast density is an important factor that can interfere with both breast cancer screening and the accurate measurement of tumor size. MRI has been widely used for this purpose, particularly for screening women with heterogeneously dense and very dense breasts, where it yields an additional cancer detection rate[22,23]. Data suggest that both MRI and CEM offer superior screening performance compared to other modalities, including in patients with dense breasts and a history of breast cancer[24,25].

In our study, FFDM demonstrated the lowest correlation with pathologic tumor size ($r = 0.314$, $p = 0.34$) and the lowest concordance rate (58.7%). These results align with prior evidence showing that FFDM can underestimate tumor size, particularly in women with dense breasts or lesions without microcalcifications[11].

In contrast, DBT and CEM demonstrated moderate-to-strong correlation with pathology ($r = 0.636$ and $r = 0.660$, respectively), while MRI achieved the highest correlation ($r = 0.811$). Tumor size agreement (within ±10 mm of pathology) reached 80.4% with MRI, followed closely by DBT and CEM (both 71.7%). These findings are consistent with prior studies showing excellent correlation between functional imaging modalities and histopathology, especially in early-stage, treatment-naïve populations[26–28].

Multifocal and contralateral lesion detection

MRI remains the most sensitive modality for detecting multifocal and contralateral lesions[6–8]. In our cohort, MRI identified multifocal disease in 15.2% of cases, compared with 8.7% by DBT and 6.5% by CEM. Although MRI numerically outperformed CEM, the difference was not statistically significant, likely due to the limited sample size. Notably, both MRI and CEM detected a contralateral invasive carcinoma in one case that was missed by FFDM and DBT, reinforcing their utility in comprehensive breast evaluation.

Failure to identify multifocal, multicentric, or contralateral lesions during preoperative staging can significantly alter the patient's treatment course. Undetected lesions may lead to incomplete tumor excision, necessitating reoperation, which can delay the initiation of adjuvant therapy and potentially compromise local control. Moreover, missing additional sites of disease may result in undertreatment, with implications for both recurrence risk and overall prognosis. In breast cancer management—where surgical planning is increasingly tailored to minimize morbidity while ensuring oncologic safety—comprehensive lesion detection is essential. MRI's high sensitivity in this context ensures that treatment strategies are based on the most accurate extent of disease, thereby optimizing both surgical outcomes and long-term survival.

MRI remains the most sensitive modality for identifying multifocal, multicentric, and contralateral breast cancer, as consistently demonstrated in large multicenter trials and meta-analyses[6–8]. This superior sensitivity has direct clinical implications, influencing surgical decision-making, such as the choice between breast-conserving surgery and mastectomy, and guiding resection margin planning. In our cohort, MRI detected multifocal disease in 15.2% of patients compared with 6.5% for CEM and 8.7% for DBT. Although these differences did not reach statistical significance, the numerical advantage of MRI aligns with prior literature, and the lack of significance is likely attributable to our limited sample size. These findings should not be interpreted as evidence of equivalence between MRI and CEM for detecting additional disease sites. Missing such lesions can result in incomplete tumor removal, the need for re-excision, or delays in initiating adjuvant therapy, all of which may adversely affect oncologic outcomes. For this reason, MRI remains the gold standard for comprehensive preoperative staging, particularly when a complete assessment of disease extent is

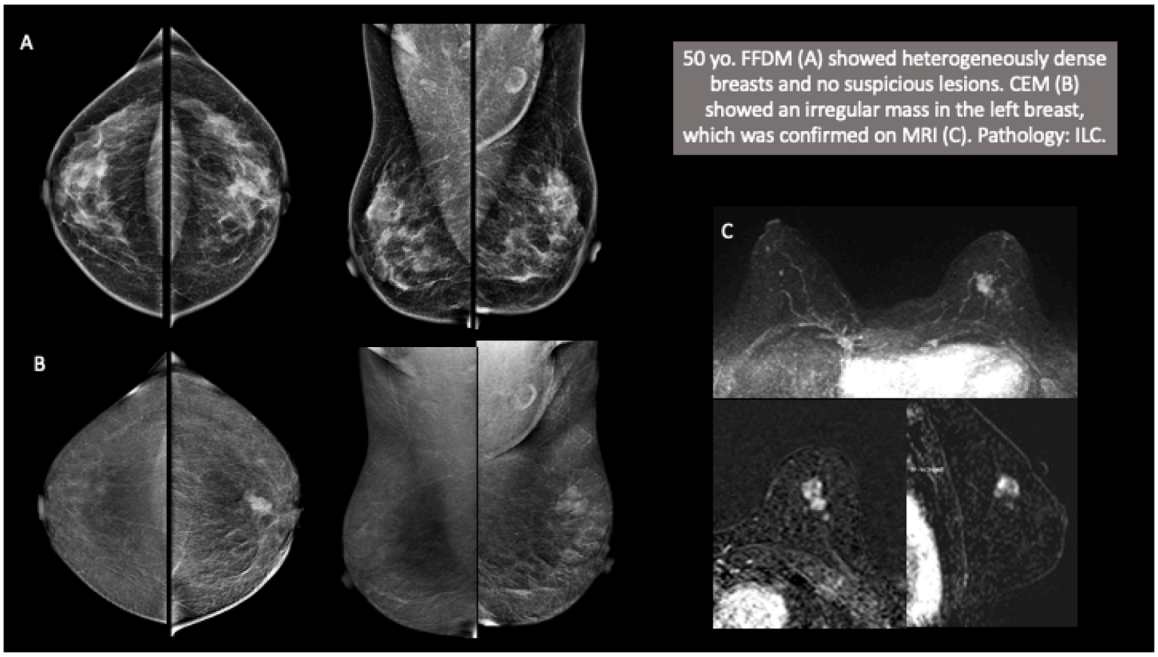

Fig. 2. Case 1, correlation between FFDM, CEM and MRI.

Table 2
Correlation and agreement between tumor size at pathology and different imaging modalities.

Imaging Modality	Pearson correlation (r)	p	Agreement
FFDM	0.314	0.34	Concordant: 27 (58.7%) Underestimated: 18 (39.1%) Overestimated: 1 (2.2%)
DBT	0.636	<0.01	Concordant: 33 (71.7%) Underestimated: 9 (19.6%) Overestimated: 4 (8.7%)
CEM	0.660	<0.01	Concordant: 33 (71.7%) Underestimated: 9 (19.6%) Overestimated: 4 (8.7%)
MRI	0.811	<0.01	Concordant: 37 (80.4%) Underestimated: 7 (15.2%) Overestimated: 2 (4.4%)

Note: Concordance was defined as a difference between imaging and pathological tumor size within ±10 mm. Overestimation was defined as a measurement >10 mm larger than the pathological size, and underestimation as a measurement >10 mm smaller than the pathological size.

Table 3
Reliability and agreement between tumor stage at pathology and different imaging modalities.

Imaging Modality	Kappa	p	Agreement
FFDM	0.274	0.01	26 (56.5%)
DBT	0.502	<0.01	34 (73.9%)
CEM	0.495	<0.01	34 (73.9%)
MRI	0.811	<0.01	38 (82.6%)

critical.

Due to the prospective nature of our study design and the low prevalence of ILC among newly diagnosed early-stage patients during the recruitment period, we were unable to include a sufficient number of ILC cases for separate analysis. We acknowledge this as a limitation, given that ILC is frequently multifocal or multicentric and MRI has been shown to outperform other modalities in accurately determining its extent[29]. We have therefore recommended that future multicenter studies include adequate representation of ILC to enable robust assessment of imaging performance in this subtype.

Table 4
Summary of main tumor characteristics, size measurements, and multifocal lesions detection across imaging modalities.

Imaging Modality	Main Tumor Detection Rate N (%)	Mean Tumor Size (cm)	Multifocal Lesions Detected N (%)
FFDM	41/46 (89.1%)	1.8 ± 0.9	0/46 (0%)
DBT	45/46 (97.8%)	2.3 ± 1.0	4/46 (8.7%)
CEM	46/46 (100%)	2.3 ± 0.9	3/46 (6.5%)
MRI	46/46 (100%)	2.5 ± 1.2	7/46 (15.2%)

Several studies have supported CEM's high sensitivity for multifocal and multicentric disease, reporting similar detection rates to MRI[24,30]. Additionally, CEM has been associated with fewer false positives and higher patient acceptance[31,32], making it an appealing alternative in settings where MRI access is limited or contraindicated.

In many healthcare systems, particularly in low- and middle-income countries, access to breast MRI is often constrained by high costs, long wait times, and limited availability of equipment and specialized personnel. Even in well-resourced settings, MRI may be contraindicated in patients with implanted devices, severe claustrophobia, or impaired renal function. In such scenarios, CEM provides a pragmatic alternative that combines morphological and functional assessment within a rapid, relatively low-cost, and widely available platform. The shorter acquisition time, greater patient comfort, and ability to integrate CEM into existing mammography units with modest modifications enable its incorporation into standard breast imaging workflows without substantial infrastructural investment. In resource-limited environments, these advantages can facilitate timely preoperative staging, reduce delays in surgical planning, and potentially improve treatment initiation timelines. While CEM should not be viewed as a universal replacement for MRI—particularly in histological subtypes such as invasive lobular carcinoma or in complex staging scenarios—it offers a valuable adjunct and, in selected cases, a feasible alternative when MRI is inaccessible or cost-prohibitive.

Access to breast MRI is frequently limited by multiple factors,

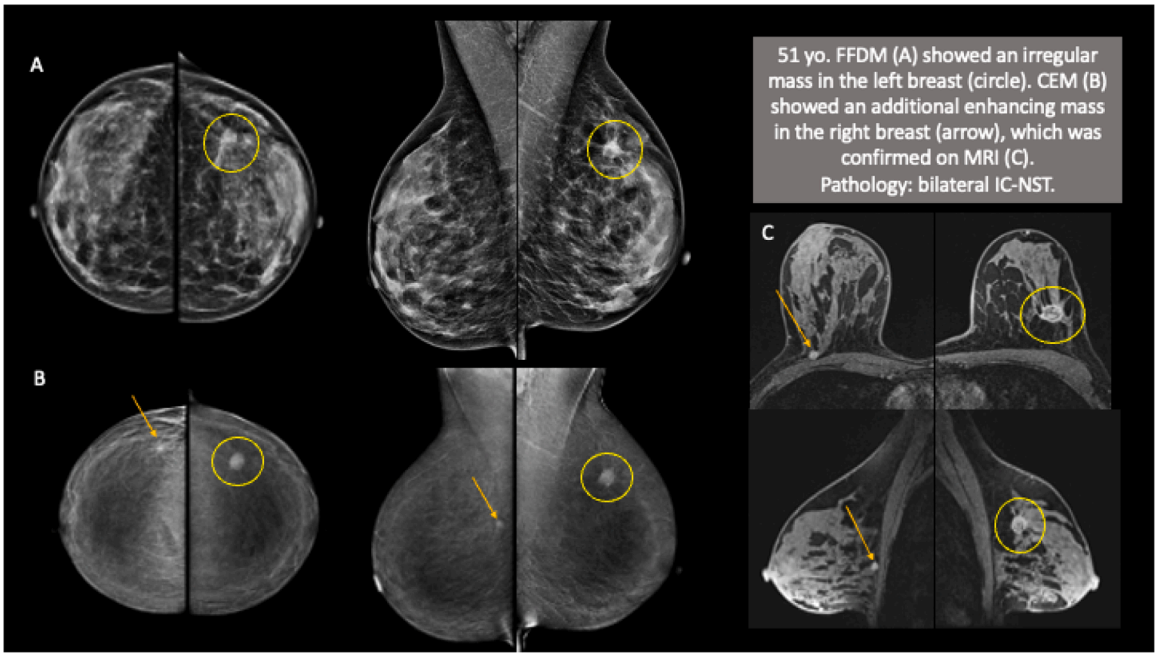

Fig. 3. Case 2, contralateral disease, correlation between FFDM, CEM and MRI.

including high acquisition and operational costs, limited availability of MRI scanners, long scheduling delays, and the need for specialized radiology expertise. Patient-related contraindications—such as implanted metallic devices, severe claustrophobia, or impaired renal function—further restrict its use. Addressing these barriers requires a multifaceted approach. Potential strategies include prioritizing MRI for high-risk or diagnostically complex cases, expanding public–private partnerships to increase scanner availability, and developing region-specific protocols to optimize resource allocation. Training breast radiologists in the acquisition and interpretation of CEM can broaden the diagnostic armamentarium in facilities where MRI access is constrained. Additionally, integrating CEM into existing mammography infrastructure offers a scalable, lower-cost option that can reduce diagnostic delays and support timely surgical planning.

Clinical utility and patient-centered considerations

Beyond diagnostic performance, practical considerations such as cost, accessibility, and patient tolerability are crucial in selecting an imaging modality. CEM offers a shorter acquisition time, lower cost, and greater availability than MRI[15,17,33]. In our study, all imaging exams were completed within one week prior to surgery, reflecting a real-world clinical workflow. While we did not perform a formal cost-effectiveness analysis, existing literature consistently supports the economic advantages of CEM over MRI[33,34].

Patient experience also influences imaging choice. MRI can be uncomfortable due to noise, prolonged duration, and the prone position. Kaiser et al. reported that most patients preferred CEM over MRI during neoadjuvant therapy, citing better tolerability and convenience[32]. These factors are particularly relevant in breast cancer care, where repeated imaging may be necessary.

Strengths and limitations

A key strength of our study is the prospective design with strict control of imaging-to-surgery intervals, reducing confounding due to tumor progression. All patients were treatment-naïve and underwent the full imaging protocol, ensuring consistency. Additionally, our analysis included both size correlation and staging concordance metrics, providing a comprehensive assessment of each modality.

This study has several limitations that should be considered when interpreting the findings. First, it was conducted at a single tertiary referral center with a relatively small sample size, which may limit the generalizability of the results to broader and more diverse patient populations. Second, ILC cases were underrepresented in our cohort. Given the well-documented challenges in detecting and assessing the full extent of ILC, and the established superiority of MRI in this context, our results should not be extrapolated to this histological subtype without caution. Third, while all imaging studies were interpreted by experienced breast radiologists, this high level of expertise may not reflect diagnostic performance in less specialized settings, potentially affecting reproducibility. Fourth, our analysis focused on tumor size and detection rates; we did not evaluate axillary or nodal disease, which is an important component of comprehensive preoperative staging. Finally, the absence of multicenter participation and the limited representation of different demographic and clinical backgrounds underscore the need for larger, prospective, multicenter studies to validate these findings.

Future directions

Future studies should expand upon our findings with multicenter designs, larger cohorts, and inclusion of diverse histological subtypes. Integrating axillary imaging, assessing inter-reader variability, and conducting cost-effectiveness analyses will help refine the role of CEM and DBT in routine preoperative staging.

Conclusion

While CEM demonstrated strong diagnostic performance and may serve as a practical alternative in certain clinical scenarios—particularly in settings where MRI is unavailable, contraindicated, or cost-prohibitive—MRI remains the gold standard for comprehensive preoperative staging in early breast cancer. This is especially true for histological subtypes such as invasive lobular carcinoma and in cases where accurate detection of multifocal, multicentric, or contralateral disease is critical for surgical planning. Our findings support the integration of CEM into preoperative staging algorithms as an adjunct or alternative to MRI in selected patients, but further multicenter studies with larger, more

diverse cohorts are warranted to confirm its role across different clinical contexts.

CRediT authorship contribution statement

André Mattar: Conceptualization, Data curation, Formal analysis, Funding acquisition, Investigation, Methodology, Project administration, Resources, Supervision, Writing – original draft, Writing – review & editing. **Almir Bitencourt:** Data curation, Formal analysis, Writing – original draft, Writing – review & editing. **Flora Finguerman Menache Dwek:** Writing – review & editing. **Andressa Amorim:** Data curation, Writing – review & editing. **Luiz Henrique Gebrim:** Writing – review & editing. **Marcelo Antonini:** Writing – review & editing. **Henrique Lima Couto:** Writing – review & editing. **Flavia Paiva:** Project administration, Writing – review & editing.

Declaration of competing interest

The authors don't have anything to disclosure.

Acknowledgements

We thank all patients enrolled in the trial.

We thank Guerbet on behalf of Cecilia Tobias de Aguiar Moeller Achcar for helping us finance the project. We also thank DASA for the infrastructure.

References

1. Bray F, et al. Global cancer statistics 2022: GLOBOCAN estimates of incidence and mortality worldwide for 36 cancers in 185 countries. *CA Cancer J Clin*. 2024;74(3):229–263.
2. Santos MdO, et al. Estimativa de incidência de câncer no Brasil, 2023-2025. *Rev Bras Cancerol*. 2023;69(1):e–213700.
3. Asaoka M, et al. Neoadjuvant chemotherapy for breast cancer: past, present, and future. *Breast Cancer (Auckl)*. 2020;14, 1178223420980377.
4. Schmid P, et al. Pembrolizumab for early triple-negative breast cancer. *N Engl J Med*. 2020;382(9):810–821.
5. Tolaney SM, et al. Adjuvant paclitaxel and trastuzumab for node-negative, HER2-positive breast cancer: final 10-year analysis of the open-label, single-arm, phase 2 APT trial. *Lancet Oncol*. 2023;24(3):273–285.
6. Houssami N, et al. Accuracy and surgical impact of magnetic resonance imaging in breast cancer staging: systematic review and meta-analysis in detection of multifocal and multicentric cancer. *J Clin Oncol*. 2008;26(19):3248–3258.
7. Morrow M, Waters J, Morris E. MRI for breast cancer screening, diagnosis, and treatment. *Lancet*. 2011;378(9805):1804–1811.
8. Turnbull L, et al. Comparative effectiveness of MRI in breast cancer (COMICE) trial: a randomised controlled trial. *Lancet*. 2010;375(9714):563–571.
9. Houssami N, Turner RM, Morrow M. Meta-analysis of pre-operative magnetic resonance imaging (MRI) and surgical treatment for breast cancer. *Breast Cancer Res Treat*. 2017;165(2):273–283.
10. Mattar A, et al. PROMERIINE: (PRe-operatory Magnetic Resonance Imaging is INEffective) Study: A Systematic Review and Meta-analysis of the Impact of Magnetic Resonance Imaging on Surgical Decisions and Clinical Outcomes in Women with Breast Cancer. *Ann Surg Oncol*. 2024;31(12):8021–8029. https://doi.org/10.1245/s10434-024-15833-5. Epub 2024 Jul 27. PMID: 39068322; PMCID: PMC11466985.
11. Şendur HN, et al. Accuracy in tumor size measurements: comparison of digital mammography, digital breast tomosynthesis and synthetic mammography. *Clin Imaging*. 2021;69:115–119.
12. Lobbes MBI, et al. Contrast enhanced mammography (CEM) versus magnetic resonance imaging (MRI) for staging of breast cancer: the pro CEM perspective. *Eur J Radiol*. 2021;142, 109883.
13. Patel BK, Lobbes MBI, Lewin J. Contrast enhanced spectral mammography: a review. *Semin Ultrasound CT MR*. 2018;39(1):70–79.
14. Tagliafico AS, et al. Diagnostic performance of contrast-enhanced spectral mammography: systematic review and meta-analysis. *Breast*. 2016;28:13–19.
15. Mori M, et al. Diagnostic accuracy of contrast-enhanced spectral mammography in comparison to conventional full-field digital mammography in a population of women with dense breasts. *Breast Cancer*. 2017;24(1):104–110.
16. Qin Y, et al. Contrast-enhanced spectral mammography: a potential exclusion diagnosis modality in dense breast patients. *Cancer Med*. 2020;9(8):2653–2659.
17. Sorin V, et al. Contrast-enhanced spectral mammography in women with intermediate breast cancer risk and dense breasts. *AJR Am J Roentgenol*. 2018;211(5):W267–w274.
18. Dromain C, et al. Contrast-enhanced digital mammography. *Eur J Radiol*. 2009;69(1):34–42.
19. Bhimani C, et al. Contrast-enhanced spectral mammography: technique, indications, and clinical applications. *Acad Radiol*. 2017;24(1):84–88.
20. Cheung YC, et al. Diagnostic performance of dual-energy contrast-enhanced subtracted mammography in dense breasts compared to mammography alone: interobserver blind-reading analysis. *Eur Radiol*. 2014;24(10):2394–2403.
21. Sardanelli F, et al. Magnetic resonance imaging of the breast: recommendations from the EUSOMA working group. *Eur J Cancer*. 2010;46(8):1296–1316.
22. Kaiser C, et al. Cancer detection rate of breast-MR in supplemental screening after negative mammography in women with dense breasts. Preliminary results of the MA-DETECT-study after 200 participants. *Eur J Radiol*. 2024;176, 111476.
23. Mann RM, Cho N, Moy L. Breast MRI: state of the art. *Radiology*. 2019;292(3):520–536.
24. Gelardi F, et al. Contrast-Enhanced Mammography versus Breast Magnetic Resonance Imaging: A Systematic Review and Meta-Analysis. *Diagnostics (Basel)*. 2022;12(8):1890. https://doi.org/10.3390/diagnostics12081890. PMID: 36010240; PMCID: PMC9406751.
25. Lobig F, et al. Performance of supplemental imaging modalities for breast cancer in women with dense breasts: findings from an umbrella review and primary studies analysis. *Clin Breast Cancer*. 2023;23(5):478–490.
26. Helal MH, et al. Staging of breast cancer and the advanced applications of digital mammogram: what the physician needs to know? *Br J Radiol*. 2017;90(1071), 20160717.
27. Lobbes MB, et al. The quality of tumor size assessment by contrast-enhanced spectral mammography and the benefit of additional breast MRI. *J Cancer*. 2015;6(2):144–150.
28. Mandoul C, et al. Breast tomosynthesis: what do we know and where do we stand? *Diagn Interv Imaging*. 2019;100(10):537–551.
29. Bahl M, Deng B. Impact of pre-operative MRI on surgical management of screening digital breast tomosynthesis-detected invasive lobular carcinoma. *Breast Cancer Res Treat*. 2024;204(2):397–405.
30. Pötsch N, et al. Contrast-enhanced mammography versus contrast-enhanced breast MRI: a systematic review and meta-analysis. *Radiology*. 2022;305(1):94–103.
31. Jochelson MS, et al. Bilateral contrast-enhanced dual-energy digital mammography: feasibility and comparison with conventional digital mammography and MR imaging in women with known breast carcinoma. *Radiology*. 2013;266(3):743–751.
32. Pires-Gonçalves L, et al. Patient perspectives on repeated contrast-enhanced mammography and magnetic resonance during neoadjuvant chemotherapy of breast cancer. *Acta Radiol*. 2023;64(5):1816–1822.
33. Waller J, et al. A primer to cost-effectiveness analysis in breast cancer imaging: a review of the literature. *Cureus*. 2022;14(8), e28356.
34. Patel BK, Gray RJ, Pockaj BA. Potential cost savings of contrast-enhanced digital mammography. *AJR Am J Roentgenol*. 2017;208(6):W231–w237.