CASE REPORT
https://doi.org/10.29289/2594539420260012

Two-stage risk-reducing breast surgery with a synthetic matrix: a case report

Amanda de Queiroz Germano[1]*, Francisco Pimentel Cavalcante[1,2], Marcelo Antonini[2,3], Antônio Luiz Frasson[2,4], Fabricio Palermo Brenelli[2,5], Felipe Pereira Zerwes[2,6], Eduardo Camargo Millen[2,7], André Mattar[2,8]

ABSTRACT

Risk-reducing mastectomy is a well-established strategy for patients at high risk of developing breast cancer, particularly those with known genetic mutations. However, in women presenting with large breasts and significant ptosis, skin-reducing mastectomy with immediate reconstruction is associated with higher rates of surgical complications, including skin flap necrosis, wound dehiscence, and implant-related issues. In this context, a staged surgical approach has been proposed as a safe alternative. The case of a 48-year-old asymptomatic woman carrying a germline pathogenic mutation in the *TP53* gene, consistent with Li-Fraumeni syndrome, who presented with large breasts and grade III ptosis is reported. In this patient, a two-stage risk-reducing surgical approach was adopted. Initially, the patient underwent reduction mammoplasty to improve breast shape and optimize skin envelope conditions. This was followed by bilateral nipple-sparing mastectomy with immediate prepectoral implant-based reconstruction assisted by a bioabsorbable synthetic matrix (GORE® BIO-A®). The study was approved by the Institutional Ethics Committee (CAAE: 73596023.4.1001.5040), and written informed consent was obtained. Postoperatively, the patient developed a localized hematoma and partial superficial nipple necrosis, both of which were managed conservatively without the need for surgical reintervention. At 60 days of follow-up, the patient presented satisfactory aesthetic outcomes, with good breast contour, no requirement for opioid analgesia, and absence of animation deformity. A staged surgical approach may reduce complications and enhance aesthetic outcomes in patients with large and ptotic breasts undergoing risk-reducing mastectomy. Prepectoral reconstruction using a bioabsorbable synthetic matrix appears to be a safe and effective option in carefully selected cases. Further prospective studies are necessary to validate these findings and establish long-term outcomes.

KEYWORDS: surgical mesh; implants; mammoplasty; mastectomy; subcutaneous mastectomy; quality of life.

INTRODUCTION

Nipple-sparing mastectomy (NSM) has become the preferred approach for mastectomies, and immediate breast reconstruction constitutes an integral component of surgical treatment for breast cancer, significantly impacting the quality of life of patients undergoing mastectomy[1]. In recent years, reconstruction with implants or expanders, submuscular or prepectoral, has gained global popularity due to its facilitation of the reconstructive process, becoming the preferred surgical modality for breast reconstruction in most centers[2,3,4].

Acellular dermal matrix (ADM) has been employed to facilitate the creation of the muscle pocket, to obtain superior control of the lower pole of reconstructed breasts or in association with prepectoral breast reconstruction, positively influencing capsular contracture rates and revision surgeries[5–7]. However, findings from various studies are contentious, often revealing higher

[1]Hospital Geral de Fortaleza – Fortaleza (CE), Brazil.
[2]Brazilian Breast Cancer Association Team – São Paulo (SP), Brazil.
[3]Hospital do Servidor Público Estadual Francisco Morato de Oliveira – São Paulo (SP), Brazil.
[4]Hospital Israelita Albert Einstein – São Paulo (SP), Brazil.
[5]Universidade Estadual de Campinas – Campinas (SP), Brazil.
[6]Pontifícia Universidade Católica do Rio Grande do Sul – Porto Alegre (RS), Brazil.
[7]Americas Oncologia – Rio de Janeiro (RJ), Brazil.
[8]Hospital da Mulher – São Paulo (SP), Brazil.
***Corresponding author:** amandaqgermano@gmail.com
Editor: none.
Received on: 03/23/2026. **Accepted on:** 04/05/2026. **Published on:** 12/06/2026.
Editora: Jordana de Faria Bessa
How to cite: Germano AQ, Cavalcante FP, Antonini M, Frasson AL, Brenelli FP, Zerwes FP, et al. Two-stage risk-reducing breast surgery with a synthetic matrix: a case report. Mastology. 2026;36:e20260012. https://doi.org/10.29289/2594539420260012

rates of complications associated with ADM[8]. Conversely, synthetic meshes offer a more economical alternative with lower complication rates but may not exert the same positive impact on breast reconstruction[9]. GORE® BIO-A® is a three-dimensional absorbable biosynthetic web frequently utilized as tissue reinforcement[10,11]. It possesses functional characteristics similar to ADMs and, due to its non-biological material composition, could theoretically demonstrate a lower complication rate compared to biological matrices.

Risk-reducing mastectomy (RRM) is a preventive surgical strategy. Advances in genetic testing have led to a growing number of women identified as carriers of pathogenic variants associated with an increased risk of breast cancer. However, many patients present an increased risk of surgical complications, especially those with large breasts and high degrees of ptosis: the use of skin-reducing mastectomies in this scenario may be associated with a higher complication rate[12,13,14]. The ideal strategy, when feasible, could be to reduce breast skin and volume in a surgical procedure separate from the preventive mastectomy[15].

This case report described an asymptomatic patient carrying a pathogenic mutation in *TP53*, who underwent bilateral RRM and immediate reconstruction in two stages: initial reduction mammoplasty followed by NSM and reconstruction with direct prepectoral implant assisted by a GORE® BIO-A® matrix.

CASE REPORT

A 48-year-old patient, carrying a germline pathogenic mutation in the *TP53* gene, was evaluated for bilateral RRM. The patient had no comorbidities. She reported menarche at 15 years of age, two pregnancies with one spontaneous abortion, and menopause at 43 years of age.

She had a family history of cancer: her mother was diagnosed with breast cancer at 62 years of age, and one of her sisters developed breast cancer at 37 years of age. The patient has five siblings (three women and two men); all female siblings were found to carry the *TP53* mutation, while the male siblings had not undergone genetic testing. She presented with large breasts and grade III ptosis (Figure 1), in addition to a high mammographic density of the breast parenchyma.

The risk-reducing surgical strategy was planned in two stages: initially, a reduction mammoplasty to decrease skin excess and breast volume, followed by RRM in a second stage (Table 1). The study was previously authorized by the Institutional Ethics Committee (CAAE: 73596023.4.1001.5040). Informed consent was obtained. This case report was prepared in accordance with the CARE guidelines.

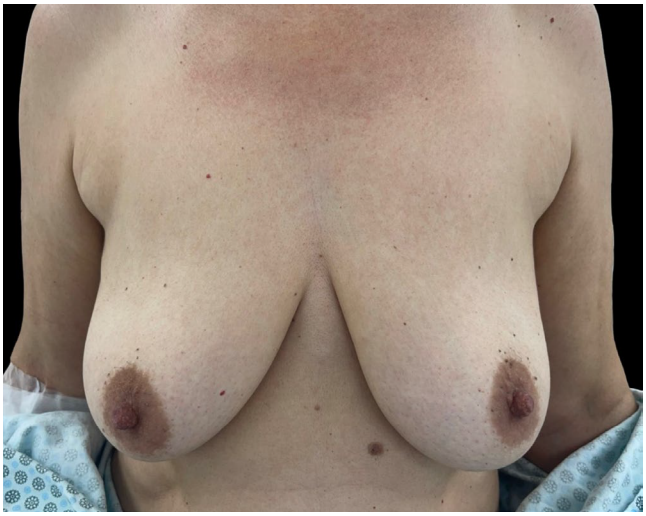

Figure 1. The patient in 2022 before the start of the breast reduction procedure.

Table 1. Timeline of events.

Time point	Clinical Event
2022	Preoperative evaluation showing large breasts; grade III ptosis; and high breast density
2022	First-stage surgery: reduction mammoplasty using Wise pattern with superomedial pedicle
December 2025	Second-stage surgery: bilateral nipple-sparing mastectomy with immediate prepectoral implant-based reconstruction assisted by GORE® BIO-A® matrix
Immediate postoperative	Drain obstruction in the left breast with localized hematoma, managed conservatively
Early postoperative	Partial superficial nipple necrosis on the right side, treated with local care
60 days postoperative	Satisfactory aesthetic outcome; no opioid requirement; absence of animation deformity; mesh no longer clinically perceptible

Surgical technique

In the first stage, reduction mammoplasty with Wise pattern resection and superomedial pedicle was performed in 2022, without complications. In December 2025, during the second phase of the strategy, RRM was recommended, involving a nipple-skin sparing mastectomy, combined with immediate reconstruction using a prepectoral implant and the use of GORE® BIO-A® mesh. The mastectomy incision was made in the inframammary fold, using the previous scar from the reduction mammoplasty. Skin flaps were developed following anatomical planes without a predefined thickness threshold. After the breast was removed, a GORE® BIO-A® mesh, measuring 9x15 cm, was divided into two equal fragments and prepared for use. The BIO-A matrix possesses a firm consistency with non-blunt edges. Prior to utilization, the matrix was hydrated with sterile 0.9% saline solution to enhance softness and flexibility, followed by trimming of the matrix edges to create blunt surfaces, thereby preventing tissue damage to the cutaneous flaps (Figure 2A).

Additionally, perforations were created throughout the matrix to mitigate seroma formation. Following this initial preparation, the matrix was positioned in the central region of the subcutaneous flap, posterior to the areola-nipple complex/vertical scar from mammoplasty (Figure 2B) for reinforcement and was sutured with absorbable sutures. Suction drains were positioned (Blake no. 19). Subsequently, implants were placed in the prepectoral position, with selection based on previous breast base measurements and desired projection. The surgical wound was closed in layers using absorbable monofilament sutures, followed by the application of sterile dressings. The final histopathological analysis did not reveal any malignancy in the breasts.

In the first few days post-surgery, the patient presented with obstruction of the left breast drain, evolving into asymmetry resulting from a local hematoma, which was treated conservatively. Superficial necrosis of the right nipple was also observed, managed with conservative treatment and local care (Figure 3A). No opioids were needed during postoperative follow-up, with pain controlled using simple analgesics (500 mg of dipyrone when necessary) and antibiotics until the drains were removed. Micropore dressings over the surgical scar were changed weekly. The presence of the mesh was immediately identifiable under the skin due to the more rigid appearance of the positioned tissue; however, after approximately 60 days post-surgery, the presence

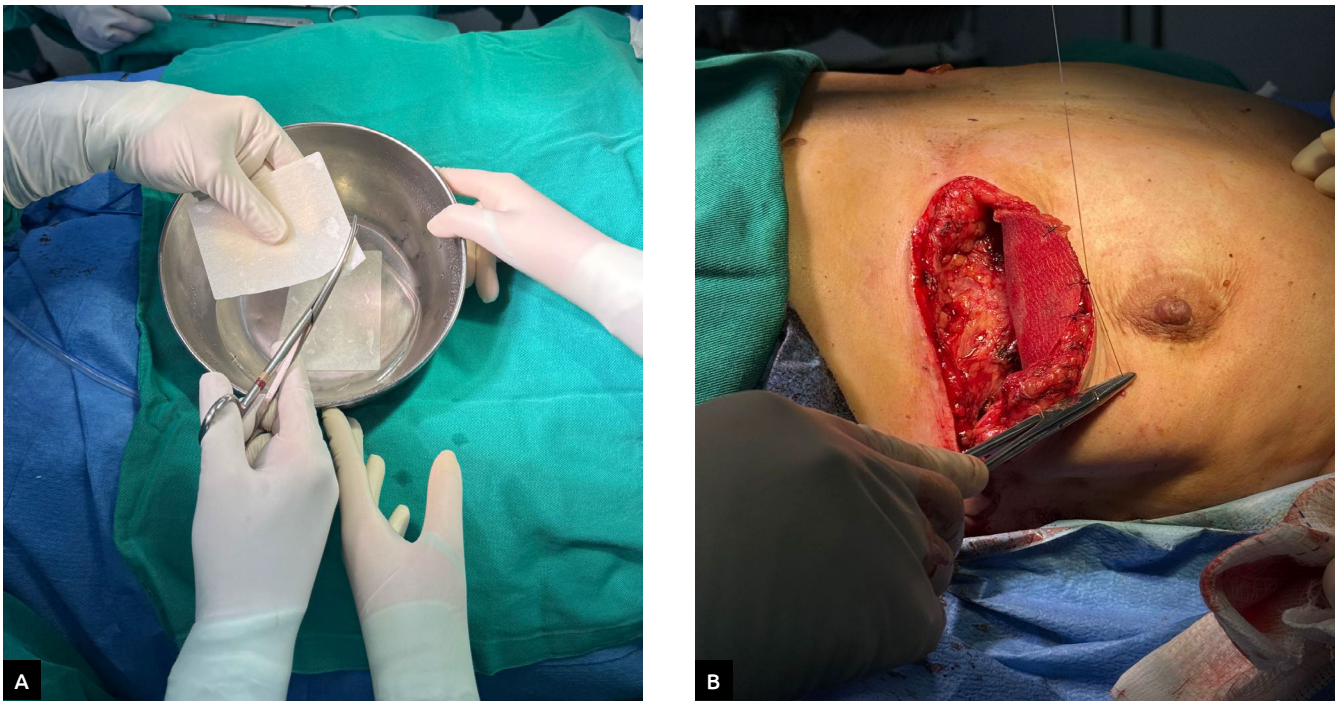

Figure 2. (A) Preparation of the GORE® BIO-A® matrix; (B) Fixation of the mesh to the subcutaneous flap.

Figure 3. (A) The patient on the thirteenth postoperative day; (B) The patient sixty days postoperatively.

of the mesh was no longer perceptible (Figure 3B). Rippling was observed in the superomedial quadrants of the reconstructed breasts, primarily the right breast. No signs of "animation" were observed (Figure 3B). Using the Harvard scale, the result was judged as satisfactory (good).

DISCUSSION

This is the case of NSM and immediate reconstruction with implant-assisted synthetic matrix in two stages, with an initial reduction mammaplasty. Contemporary reconstruction aims to achieve adequate breast volume and create a new breast with appropriate contours, texture, and symmetry, being especially important in RRMs in asymptomatic patients. Hybrid reconstruction, employing implants and meshes, serves this purpose.

The literature describes numerous mesh options, both biological and synthetic, with conflicting results regarding immediate and late outcomes[8]. While offering lower costs and potentially reduced complication rates compared to biological matrices, synthetic meshes may not achieve the aesthetic results associated with ADMs. A study involving 39 patients and 78 breasts comparing polyglactin synthetic mesh found that ADM was associated with reduced capsular contracture and implant malpositioning[9]. The study yielded satisfactory aesthetic results in short-term follow-up using the GORE® BIO-A® bioabsorbable matrix, a product with few reports in the literature, but with promising initial results[16].

A significant topic of interest is prepectoral reconstruction with implants. In recent years, prepectoral reconstruction has gained popularity among surgeons because it facilitates immediate breast reconstruction with implants, in a physiological plane, with acceptable complication rates and reduced pectoral muscle animation[17,18]. On the other hand, literature data do not consistently indicate a requirement for matrices in all prepectoral reconstruction cases, as used in this case[4]. However, it is postulated that matrix utilization may be beneficial in cases with inadequate flaps, also intended for initial mechanical reinforcement, especially in patients who have recently undergone mammoplasty, although this scenario is recognized as a matter of controversy. Without a doubt, another advantage of the prepectoral plane, especially in an asymptomatic patient in the context of RRM, would be pain control. A study evaluating narcotic use among patients undergoing dual-plane submuscular versus prepectoral plane reconstructions after mastectomy demonstrated a 66% reduction in opioid prescription in the latter, as well as fewer days of use in those who used them[19]. In the present case, no opioid use was required after surgery, with mild pain controlled by simple analgesics. Finally, another beneficial point of using the prepectoral plane was the absence of animation of the reconstructed breasts, consistent with the literature. A meta-analysis of patients undergoing prepectoral versus submuscular reconstruction with 3,101 patients in 15 studies demonstrated less animation deformity in the prepectoral plane (odds ratio 0.02 [0.00-0.25])[20].

A crucial point for achieving a good result with a low complication profile is the appropriate selection of the technique for each patient. Small breasts without ptosis are natural candidates for NSM and reconstruction with definitive implants, either prepectoral or submuscular. On the other hand, for breasts with greater volume and pronounced ptosis, the combination of skin reduction to achieve a better aesthetic result may be beneficial. However, performing skin reduction concomitantly with conservative mastectomy, in the so-called skin-reducing mastectomy, may be associated with a higher complication rate, regardless of the type of implant, use of mesh, or submuscular placement. A meta-analysis of 28 studies and over 1,200 reconstructed breasts demonstrated that areola-nipple complex necrosis is more frequent in this population[12.] Furthermore, a meta-analysis of over 1,000 reconstructed breasts in 24 studies, using skin-reducing mastectomy and an inferior dermal flap, demonstrated complication rates above 20%, with limited evidence in the literature[14]. In this context, the use of mastectomy skin reduction should be evaluated very carefully in the therapeutic setting when it is not possible to perform skin reduction prior to mastectomy, as planned in this case because it involved a high-risk but asymptomatic patient. Two-stage risk-reducing surgery may be a less risky approach in this scenario.

CONCLUSION

In asymptomatic patients with large breasts and/or marked ptosis who are recommended for RRM, the use of a two-stage strategy — mammoplasty followed by NSM-type mastectomy and reconstruction with implants — may be a lower-risk approach in terms of complications. The use of the prepectoral plane in well-defined situations, with or without the addition of matrices, can facilitate surgical and postoperative management, impacting the cosmetic outcome. More studies are needed in this scenario.

ACKNOWLEDGEMENT

The authors are grateful to the pacient for consenting to publication of this case.

AUTHORS' CONTRIBUTIONS

AQG: Conceptualization, Data curation, Formal analysis, Funding acquisition, Investigation, Methodology, Project administration, Supervision, Validation, Visualization, Writing – original draft, Writing – review & editing. FPC: Conceptualization, Data curation, Formal analysis, Funding acquisition, Investigation, Methodology, Project administration, Supervision, Validation,

Visualization, Writing – original draft, Writing – review & editing. MA: Conceptualization, Data curation, Formal analysis, Funding acquisition, Investigation, Methodology, Project administration, Supervision, Validation, Visualization, Writing – original draft, Writing – review & editing. ALF: Conceptualization, Data curation, Formal analysis, Funding acquisition, Investigation, Methodology, Project administration, Supervision, Validation, Visualization, Writing – original draft, Writing – review & editing. FPB: Conceptualization, Data curation, Formal analysis, Funding acquisition, Investigation, Methodology, Project administration, Supervision, Validation, Visualization, Writing – original draft, Writing – review & editing. FPZ: Conceptualization, Data curation, Formal analysis, Funding acquisition, Investigation, Methodology, Project administration, Supervision, Validation, Visualization, Writing – original draft, Writing – review & editing. ECM: Conceptualization, Data curation, Formal analysis, Funding acquisition, Investigation, Methodology, Project administration, Supervision, Validation, Visualization, Writing – original draft, Writing – review & editing. AM: Conceptualization, Data curation, Formal analysis, Funding acquisition, Investigation, Methodology, Project administration, Supervision, Validation, Visualization, Writing – original draft, Writing – review & editing.

Funding: none.
Conflict of interests: nothing to declare.
Artificial intelligence usage: none.
Data availability statement: sensitive or confidential data.

REFERENCES

1. Cordeiro PG. Breast reconstruction after surgery for breast cancer. N Engl J Med. 2008;359(15):1590-601. https://doi.org/10.1056/nejmct0802899
2. Lanitis S, Tekkis PP, Sgourakis G, Dimopoulos N, Al Mufti R, Hadjiminas DJ. Comparison of skin-sparing mastectomy versus non-skin-sparing mastectomy for breast cancer: a meta-analysis of observational studies. Ann Surg. 2010;251(4):632-9. https://doi.org/10.1097/sla.0b013e3181d35bf8
3. Albornoz CR, Bach PB, Mehrara BJ, Disa JJ, Pusic AL, McCarthy CM, et al. A paradigm shift in U.S. breast reconstruction: increasing implant rates. Plast Reconstr Surg. 2013;131(1):15-23. https://doi.org/10.1097/prs.0b013e3182729cde
4. Urban C, González E, Fornazari A, Berman G, Spautz C, Kuroda F, et al. Prepectoral direct-to-implant breast reconstruction without placement of acellular dermal matrix or mesh after nipple-sparing mastectomy. Plast Reconstr Surg. 2022;150(5):973-83. https://doi.org/10.1097/prs.0000000000009618
5. Nahabedian MY, Spear SL. Acellular dermal matrix for secondary procedures following prosthetic breast reconstruction. Aesthet Surg J. 2011;31(Suppl 7):38S-50S. https://doi.org/10.1177/1090820x11418093
6. Ellsworth WA, Hammer J, Luo L, Schumacher A. Acellular dermal matrices in breast reconstruction: CARE trial 5-year outcomes data for more than 9500 patients. Plast Reconstr Surg Glob Open. 2022;10(4):e4258. https://doi.org/10.1097/gox.0000000000004258
7. Reitsamer R, Peintinger F, Klaassen-Federspiel F, Sir A. Prepectoral direct-to-implant breast reconstruction with complete ADM or synthetic mesh coverage: 36-month follow-up in 200 reconstructed breasts. Breast. 2019;48:32-7. https://doi.org/10.1016/j.breast.2019.08.002
8. Lohmander F, Lagergren J, Johansson H, Roy PG, Brandberg Y, Frisell J. Effect of immediate implant-based breast reconstruction after mastectomy with and without acellular dermal matrix among women with breast cancer: a randomized clinical trial. JAMA Netw Open. 2021;4(10):e2127806. https://doi.org/10.1001/jamanetworkopen.2021.27806
9. Silverstein ML, Momeni A. Long-term outcomes following hybrid breast reconstruction. Plast Reconstr Surg. 2024;154(2):217e-23e. https://doi.org/10.1097/prs.0000000000010987
10. Sutton PA, Evans JP, Uzair S, Varghese JV. The use of Gore Bio-A in the management of the open abdomen. BMJ Case Rep. 2013;2013:bcr2013000000. https://doi.org/10.1136/bcr-2012-008064
11. Clapp B, Kara AM, Nguyen-Lee PJ, Alvarado L, Marr JD, Annabi HM, et al. Does the use of bioabsorbable mesh for hiatal hernia repair at the time of bariatric surgery reduce recurrence rates? A meta-analysis. Surg Obes Relat Dis. 2022;18(12):1407-15. https://doi.org/10.1016/j.soard.2022.08.004
12. Darras O, Phuyal D, Kornfeld H, Bernard S, Hansen J, Bishop SN, et al. Nipple-preserving skin-reducing mastectomy in ptotic breasts: a systematic review and meta-analysis. Ann Plast Surg. 2026;96(3):298-308. https://doi.org/10.1097/sap.0000000000004613
13. Cheong SC, Maliekkal J, Tung WS, Saadya A, Awad GA. Wise versus vertical mastopexy pattern skin-reducing mastectomy with immediate breast reconstruction: systematic review and meta-analysis. Plast Reconstr Surg Glob Open. 2025;13(3):e6584. https://doi.org/10.1097/gox.0000000000006584
14. Jepsen C, Hallberg H, Pivodic A, Elander A, Hansson E. Complications, patient-reported outcomes, and aesthetic results in immediate breast reconstruction with a dermal sling: a systematic review and meta-analysis. J Plast Reconstr Aesthet Surg. 2019;72(3):369-80. https://doi.org/10.1016/j.bjps.2018.12.046

15. Gunnarsson GL, Thomsen JB. Prophylactic nipple-sparing mastectomy and direct-to-implant reconstruction of the large and ptotic breast: is preshaping of the challenging breast a key to success? Plast Reconstr Surg. 2018;141(6):960e-1e. https://doi.org/10.1097/prs.0000000000004382

16. Cavalcante FP, Zerwes FP, Millen EC, Mattar A, Antonini M, Brenelli FP, et al. Assisted breast reconstruction with biosynthetic mesh and implants: a pilot study. Plast Reconstr Surg Glob Open. 2025;13(12):e7328. https://doi.org/10.1097/GOX.0000000000007328

17. Cavalcante FP, Lima TO, Alcantara R, Cardoso A, Ulisses F, Novita G, et al. Inframammary versus periareolar incision: a comparison of early complications in nipple-sparing mastectomy. Plast Reconstr Surg Glob Open. 2023;11(11):e5367. https://doi.org/10.1097/gox.0000000000005367

18. Cavalcante FP, Lima TO, Alcantara R, Cardoso A, Novita G, Zerwes F, et al. Immediate prepectoral versus submuscular breast reconstruction in nipple-sparing mastectomy: a retrospective cohort analysis. Rev Bras Ginecol Obstet. 2024;46:e-rbgo76. https://doi.org/10.61622/rbgo/2024rbgo76

19. Copeland-Halperin LR, Yemc L, Emery E, Collins D, Liu C, Mesbahi AN, et al. Evaluating postoperative narcotic use in prepectoral versus dual-plane breast reconstruction following mastectomy. Plast Reconstr Surg Glob Open. 2019;7(2):e2082. https://doi.org/10.1097/gox.0000000000002082

20. Ostapenko E, Nixdorf L, Devyatko Y, Exner R, Wimmer K, Fitzal F. Prepectoral versus subpectoral implant-based breast reconstruction: a systematic review and meta-analysis. Ann Surg Oncol. 2023;30(1):126-36. https://doi.org/10.1245/s10434-022-12567-0

© 2026 Brazilian Society of Mastology
This is an open access article distributed under the terms of the Creative Commons license.